Advances in Medical, Pharmaceutical and Dental Research Journal (AMPDR)- ISSN 2812-4898
http://dx.doi.org/10.21622/AMPDR.2026.06.2.2379
Copyright © 2026, authors
June 2026
Volume 6
Issue 2

Prosthetic Rehabilitation of a Migrated Canine Serving as a Pier Abutment Using a Non-Rigid Connector and Digital Workflow: A Case Report

Prasanna Lingala, Rajyalakshmi Ravuri and Praveen Mamidi
Panineeya Mahavidyalaya Institute of Dental Sciences and Research Centre, India

Emails: lingalaprasanna97@gmail.com, rajyambottu@gmail.com, praveenprostho@gmail.com

Received 12 July 2026 - Accepted 08 August 2026 - Published 23 September 2026

ABSTRACT:

Background: *Pier abutments present a distinct biomechanical challenge in fixed partial denture (FPD) design, as the presence of an intermediate abutment between two edentulous spans can lead to unfavorable stress distribution. The incorporation of nonrigid connectors offers a practical solution, allowing controlled, independent movement of prosthetic segments and thereby minimizing stress concentration around the pier abutment.*

Case Description: *A 52-year-old male patient presented with partial edentulism involving the maxillary anterior and posterior regions as well as the mandibular posterior segment. His medical history was non-contributory, and the tooth loss was attributed to periodontal disease. Clinical evaluation revealed distal migration of the maxillary left canine into the site of the missing first premolar, resulting in an atypical edentulous pattern. This positional change rendered the migrated canine an intermediate pier abutment within the prosthetic design. [Figure 1]. A segmented fixed partial denture was planned to extend from tooth 22 to 26. The migrated maxillary left canine was preserved and recontoured to resemble premolar morphology, while the original canine site was restored with a canine pontic shaped anatomy. To manage the pier abutment situation, a non-rigid key-and-keyway connector was incorporated between teeth 24 and 26, with the keyway positioned in 24 and the key in 26. A diagnostic wax mock-up was fabricated, followed by polymethyl methacrylate (PMMA) verification templates to guide tooth preparation. Intraoral digital Scanning was performed, and the data were exported as an STL file for computer-aided design and direct metal laser sintering (DMLS) fabrication of a porcelain-fused-to-metal prosthesis. Cervical staining was reproduced in the definitive restoration to achieve optimal esthetics.*



Figure 1: Preoperative photograph

Conclusion:
Individualized prosthetic planning, combined with the use of a non-rigid connector and digitally assisted fabrication techniques, provided an effective strategy for the rehabilitation of a complex pier abutment scenario resulting from tooth migration.

KEYWORDS:

Pier abutment; Non-rigid connector; Fixed partial denture; Tooth migration; Digital prosthodontics; DMLS; Metal-ceramic restoration.

Advances in Medical, Pharmaceutical and Dental Research Journal (AMPDR)- ISSN 2812-4898
http://dx.doi.org/10.21622/AMPDR.2026.06.2.2379

1. Introduction

Fixed partial dentures continue to serve as a valuable treatment modality for patients with partial edentulism. A pier abutment situation arises when a natural tooth is positioned between two edentulous spans, thereby functioning as an intermediate abutment for adjacent prosthetic segments. [1]. Rigid connection of prosthetic segments in a pier abutment situation can lead to unfavorable force transmission and the development of a fulcrum effect around the intermediate abutment. The use of non-rigid connectors permits controlled, independent movement between segments and may help mitigate stress concentration [2]. Rehabilitation becomes further complicated when tooth migration occurs following tooth loss, as this alters the mesiodistal space and disrupts normal occlusal relationships. [3]. In complex clinical scenarios, modification of tooth morphology may be necessary to achieve satisfactory function and esthetics. The present case illustrates the management of an atypical pier abutment condition, resulting from distal migration of the maxillary canine into the premolar region, through the use of a non-rigid connector integrated with a digitally assisted workflow.

2. Case Report:

A 52-year-old male patient presented to the Department of Prosthodontics with a chief complaint of missing teeth in the maxillary anterior and posterior regions, as well as the mandibular posterior segment, with a duration of a few months. His medical history was non-contributory, and the tooth loss was attributed to periodontal disease. Clinical examination revealed a Kennedy Class III partially edentulous maxillary arch. The maxillary left canine (23) had migrated distally into the site of the missing first premolar (24), leaving the original canine region edentulous and creating two separate edentulous spaces divided by the migrated canine. Consequently, the canine functioned as an intermediate pier abutment. Grade I gingival recession was noted in relation to 23, without mobility. The patient exhibited a Class I molar relationship and an end-on-end anterior incisal relationship, with no parafunctional habits reported. In the mandibular arch, the left second molar (37) was absent, and rehabilitation with a fixed prosthesis involving teeth 36, 37, and 38 was planned independently. Radiographic evaluation demonstrated favorable root morphology, with no evidence of periapical pathology or significant periodontal compromise. Teeth 22, 23, and 26 had undergone endodontic treatment and retained sufficient coronal tooth structure; therefore, a post-and-core procedure was not indicated.

A segmented fixed partial denture was designed to involve teeth 22, 23, 24, and 26. The migrated natural canine occupying the 24 region was retained and transformed into a premolar-like tooth with premolar occlusal anatomy, while the original canine space was restored with a canine-shaped pontic. Due to the reduced mesiodistal dimension, the premolar morphology was proportionally enlarged, and the occlusal table of tooth 26 was broadened to compensate for the limited space and establish functional occlusal contacts. To address the pier abutment situation, a non-rigid key-and-keyway connector was incorporated between teeth 24 and 26, with the keyway positioned in 24 and the key in 26. The existing Class I molar relationship was maintained throughout the prosthetic design.



Figure 2: Wax mockup

Before tooth preparation, an inlay wax diagnostic mock-up was fabricated [Figure 2] to evaluate tooth morphology, esthetics, prosthetic space, and occlusion. The mock-up was sent to the laboratory, where PMMA preparation verification templates were fabricated [Figure 3].



Figure 3: Template received from Lab

Intraoral verification templates were employed to guide tooth reduction in accordance with the planned prosthetic contours. A radial shoulder finish line was established. Tooth 22 underwent approximately 1.5 mm incisal reduction and 1.5–2 mm facial and palatal reduction, while tooth 26 received 1.5–2 mm occlusal and axial reduction. The migrated canine in the premolar region (24) required additional reduction to accommodate its modified premolar morphology and the incorporation of the non-rigid connector. The preparation was adjusted to a relatively conical configuration, with substantial modification of the existing occlusal anatomy. [Figure 4]. Gingival displacement was accomplished using a single 000-sized retraction cord impregnated with a hemostatic agent. Instead of conventional impression techniques, an intraoral digital scan was performed, and the data were exported as an STL file for laboratory fabrication. [Figure 5].



Figure 4: Tooth Preparation done

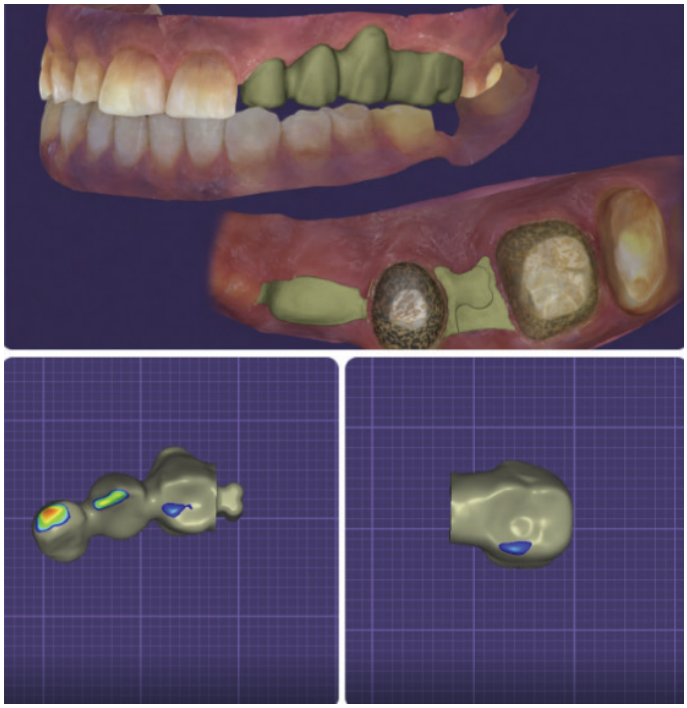

Figure 5: Scanning and designing of prosthesis with EXOCAD software

The digital workflow comprised intraoral Scanning, virtual articulation, prosthetic design, and direct metal laser sintering (DMLS) framework fabrication. The specific CAD software and alloy composition used for the framework were not documented. A metal framework trial was conducted intraorally to assess fit, marginal integrity, connector engagement, proximal contacts, and occlusion. Shade selection was performed prior to tooth preparation, and the digital scan facilitated evaluation of shade characteristics. Cervical staining observed in the natural dentition was replicated in the definitive porcelain restoration to achieve esthetic harmony [Figure 6]. Provisional restorations were provided during the laboratory phase. The definitive DMLS porcelain-fused-metal prosthesis was finally cemented using Ivoclar glass ionomer luting cement [Figure 7].



Figure 6: Metal framework

Advances in Medical, Pharmaceutical and Dental Research Journal (AMPDR)- ISSN 2812-4898
http://dx.doi.org/10.21622/AMPDR.2026.06.2.2379





Figure 6: Ceramic buildup & Final Cementation

Occlusal adjustment was performed after cementation, with the pre-existing Class I molar relationship maintained [Figure 8]. The immediate clinical outcome was satisfactory in terms of fit, esthetics, and function. As the prosthesis was recently delivered, long-term follow-up was not available.



Figure 8: Class I Molar Relation maintained.

3. Discussion:

Pier abutment situations present distinctive biomechanical challenges, as the intermediate abutment separates two prosthetic segments that may respond differently to functional loading. When rigidly connected, occlusal forces can be transmitted through the pier abutment, potentially creating a fulcrum effect and concentrating stress [4]. Incorporation of a non-rigid connector permits controlled, independent movement between segments and helps reduce the magnitude of forces transferred to the intermediate abutment. In the present case, a key-and-keyway connector was strategically positioned between teeth 24 and 26, with the keyway in 24 and the key in 26.

A unique feature of this case was the distal migration of the natural canine into the premolar region, producing an altered edentulous configuration. Rather than attempting orthodontic repositioning, the existing tooth position was utilized prosthetically. The migrated canine was recontoured to resemble premolar morphology, while the original canine site was restored with a canine-shaped pontic. The reduced mesiodistal dimension necessitated enlargement of the premolar form and modification of the molar occlusal table to establish appropriate posterior contacts. This approach enabled functional rehabilitation without orthodontic redistribution of space.

The case highlights the integration of conventional prosthodontic principles with contemporary digital technology. A diagnostic wax-up established the desired morphology, and PMMA verification templates facilitated precise transfer of planned tooth reduction. Intraoral Scanning eliminated the need for conventional impressions and provided STL data for laboratory processing [5]. Virtual articulation, digital design, direct metal laser sintering (DMLS) fabrication, and porcelain characterization ensured accurate reproduction of the planned prosthesis [6]. Cervical staining was incorporated to enhance esthetic integration with the natural dentition.

Although implant-supported prostheses are often considered in partially edentulous cases, treatment must be individualized according to clinical circumstances, spatial constraints, patient preferences, and prosthetic requirements. In this case, the combination of a non-rigid connector,

prosthetically driven space management, and digital fabrication offered a predictable and practical solution for the rehabilitation of a complex pier abutment situation.

Clinical Significance:

Distal migration of a tooth can create an atypical pier abutment configuration and significantly alter the available prosthetic space. Careful prosthetic planning, appropriate placement of non-rigid connectors, modification of tooth morphology, and integration of digital workflows provide a reliable approach for managing such challenging clinical scenarios.

4. Limitations

This case report presents a novel approach to rehabilitating a migrated canine functioning as a pier abutment through the use of a non-rigid connector and a digitally assisted workflow. Its primary limitation lies in the single-patient design, which restricts generalizability. Furthermore, as the prosthesis was only recently delivered, long-term follow-up is necessary to evaluate periodontal health, cementation integrity, connector performance, occlusal stability, and overall prosthesis longevity. Broader clinical studies with extended follow-up and biomechanical validation are required to substantiate the effectiveness of this approach.

5. Conclusion

Management of a migrated tooth serving as a pier abutment requires individualized consideration of tooth position, prosthetic space, biomechanical factors, and occlusal relationships. In this case, a segmented fixed partial denture incorporating a non-rigid key-and-keyway connector facilitated controlled distribution of functional forces between prosthetic segments. Transformation of the migrated canine into premolar-like morphology, along with modification of the molar occlusal table, enabled efficient utilization of the available space while preserving the existing occlusal scheme. The integration of diagnostic wax-up, PMMA verification templates, intraoral Scanning, digital design, and direct metal laser sintering (DMLS) fabrication underscores the potential of combining conventional prosthodontic principles with digital technology for the rehabilitation of complex fixed prosthodontic cases.

Authors' Contributions:

1. Dr. Prasanna: Manuscript writing, Investigation, Intellectual content
2. Dr. Ravuri Rajyalakshmi: Concept, Design, Intellectual content
3. Dr. Mamidi Praveen: Investigation, Intellectual content

Declarations and Confirmations

- Originality and Exclusive Submission: The authors confirm that this manuscript is original, has not been published previously, and is not under consideration for publication elsewhere.
- Corresponding Author Responsibility: The submitting author accepts responsibility for the submission on behalf of all coauthors and will serve as the corresponding author for all editorial communications.
- Author Approval and Accountability: All authors have reviewed and approved the final version of the manuscript, consent to its submission, and meet the journal's criteria for authorship. Each author accepts responsibility for the accuracy and integrity of the work.
- Journal Policy Issues: No ethical, legal, or policy issues are outstanding.
- Funding: No external funding
- Acknowledgments: The authors would like to thank the patient for their support in this case study.
- AI Disclosure: Microsoft Copilot was used for proofreading, grammar correction, and language improvement. The authors reviewed, edited, and take full responsibility for all AI-generated content.

Advances in Medical, Pharmaceutical and Dental Research Journal (AMPDR)- ISSN 2812-4898
http://dx.doi.org/10.21622/AMPDR.2026.06.2.2379

References

1. Raj R B, Kaur P, Rani P D, R V. Prosthodontic management of a pier abutment using a digitally designed non-rigid connector: A clinical case report. International Journal of Oral Health Dentistry [Internet]. 2025 Oct 14 [cited 2026 Sept 7];11(3):251–5. Available from: https://doi.org/10.18231/j.ijohd.12834.1759135837

2. Kanojia EM, Bhoyar A, Dubey SR, Sathe S, Khubchandani SR, Shinde R. Shielding the pier abutment using a nonrigid connector. Cureus. 2024 Jan 25;16(1).

3. V Suresh. Pathological migration associated with loss of posterior teeth. International Journal of Dentistry and Oral Science. 2020 Oct 24;7(11):903–7.

4. Ebadian B, Fathi A, Tabatabaei S. Stress distribution in 5-Unit fixed partial dentures with a pier abutment and rigid and nonrigid connectors with two different occlusal schemes: A three-dimensional finite element analysis. International Journal of Dentistry. 2023 Feb 1;2023:1–15.

5. Turkyilmaz I, Wilkins GN, Benli M. Relationship between the data quality of digital scans from intraoral scanners and surface topography of prepared teeth. Journal of Dental Sciences. 2021 Jan;17(1):592–4.

6. Abduo J, Rasaie V. Digital Workflows in Prosthodontics. Australian dental journal [Internet]. 2025 [cited 2026 Sept 7];70(Supplement 1 (S1)):10.1111/adj.70005. Available from: https://pubmed.ncbi.nlm.nih.gov/40952009/