

# Adhering to Basic Principles in a Rare Dental Condition: A Case Report of Severe Dilaceration

JAVANMARDI Shahab<sup>1</sup> and QUTIESHAT Abubaker<sup>2</sup>

<sup>1,2</sup> Adult Restorative Dentistry, Oman Dental College

Email: [sjavanmardi@staff.odc.edu.om](mailto:sjavanmardi@staff.odc.edu.om), [aqutieshat@staff.odc.edu.om](mailto:aqutieshat@staff.odc.edu.om)

Received on, 04 March 2023 - Accepted on, 09 April 2023 - Published on, 20 April 2023

## Abstract:

**Background:** Dilaceration is a rare dental condition that can occur during tooth development, resulting in distortion of the normal axial relationship between the crown and root. Although it can affect any tooth, it most commonly occurs in permanent incisors, often as a result of trauma to the primary predecessor. The impact of even a slight displacement of a primary incisor can be significant, disrupting the normal development of the follicles of new permanent teeth. Despite its rarity, dilaceration can pose significant challenges for dental professionals in terms of diagnosis and treatment. Case

**Description:** A case report of a 27-year-old female patient is presented, who attended with a missing maxillary left permanent central incisor and a hard palpable bulge in the maxillary vestibular area. Radiography revealed an impacted maxillary left central incisor, which was found to be dilacerated with a 120° angle. Consequently, surgical extraction of the impacted tooth was planned as orthodontic extrusion is not a viable option in such cases. The extracted tooth was found to have no signs of resorption, and healing was progressing satisfactorily.

**Conclusion:** Radiography is the most reliable method of detecting the condition. The report emphasizes the importance of detecting dilaceration early and adhering to basic principles for its diagnosis and management. **Clinical Significance:** The report provides valuable insights for dental professionals on the surgical management of severely dilacerated teeth and the need for a multidisciplinary approach due to the high risk of root fractures.

**Key words:** Dilaceration; Diagnosis; Impaction; Injury

## 1. Introduction

Dilaceration is a complex and relatively uncommon condition that can occur during tooth development, leading to a distortion in the normal axial relationship between the crown and root. Although dilacerations can affect any tooth, they most commonly occur in permanent

incisors, often as a result of trauma to the primary predecessor that is in close proximity to the developing permanent tooth germ. In rare cases, dilaceration may occur as a result of unknown developmental factors <sup>[1,2]</sup>.

The impact of even a slight displacement of a primary incisor can be significant, disrupting the normal development of the follicles of new permanent teeth. Dilacerations affecting the permanent dentition following trauma to the primary dentition are uncommon, but they can have significant consequences for affected individuals <sup>[3]</sup>. While dilaceration can occur in any tooth, the prevalence of dilaceration for maxillary central incisors has been reported to be within the range of 0.1% to 1.0%, making it a relatively rare condition <sup>[4-6]</sup>.

Despite its rarity, dilaceration can pose significant challenges for dental professionals in terms of diagnosis and treatment. The complex nature of this condition requires a thorough understanding of the underlying causes and diagnostic methods to enable effective treatment planning.

## 2. Case Report

A 27-year-old Caucasian female reported to the Department of Orthodontics and was concerned about her malaligned maxillary anterior teeth and the absence of her maxillary left permanent central incisor. Interestingly, the patient had attended a different dental office 24 years earlier with an intruded maxillary left primary central incisor due to trauma. Her dental records indicated that when she presented back then, she was symptomless, and the intruded tooth was extracted by the attending dentist.

Clinically, the patient had a removable partial denture replacing the missing maxillary left permanent central incisor. She had a class I canine relationship with normal overjet and moderate anterior spacing. Four molars were missing, the right maxillary and mandibular first molars, and the left mandibular first and third molars which may have been removed due to dental pathological conditions.

There was a hard palpable bulge in the maxillary

vestibular area (Figure 1A). Upon radiographical examination, a "bull's eye" image was observed on both the Orthopantomogram (OPG) and periapical radiographs. This peculiar image is generated by a radiopaque mass with a central radiolucent area formed by the pulp chamber and the root canal and was described previously in the literature (Figure 1B) [7].

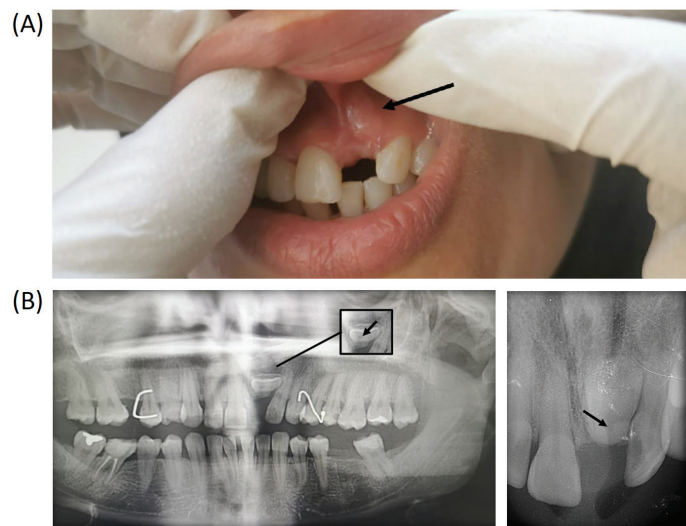


Figure 1. (A) Pre-operative image of the area of concern showing a hard palpable labial bulge. (B) Radiographic examination. The characteristic bull's eye image is observed on the OPG radiograph (Left) and the periapical radiograph (right).

Analysis of radiographs revealed that there was an impacted maxillary left central incisor. Given the characteristic feature of the radiopaque mass with a bull's eye that was shown in both radiographic images, and the fact that such peculiar appearance is associated with a dilaceration angle of 90 degrees or more, it was determined that the tooth is dilacerated. Consequently, surgical extraction of the impacted tooth was planned as orthodontic extrusion is not a viable option in such cases.

Thereafter, presurgical assessment was carried out, including detailed clinical and medical history and the surgery was undertaken shortly after under local anesthesia (2% lidocaine with epinephrine (1: 100,000)). An incision was made, and a buccal flap was elevated exposing the alveolar bone and the unerupted dilacerated tooth. The labial surface of the cervical third of the root was immediately visible as the patient had a dehiscence defect of 8.0 mm x 6.0 mm at that site (Figure 2A).

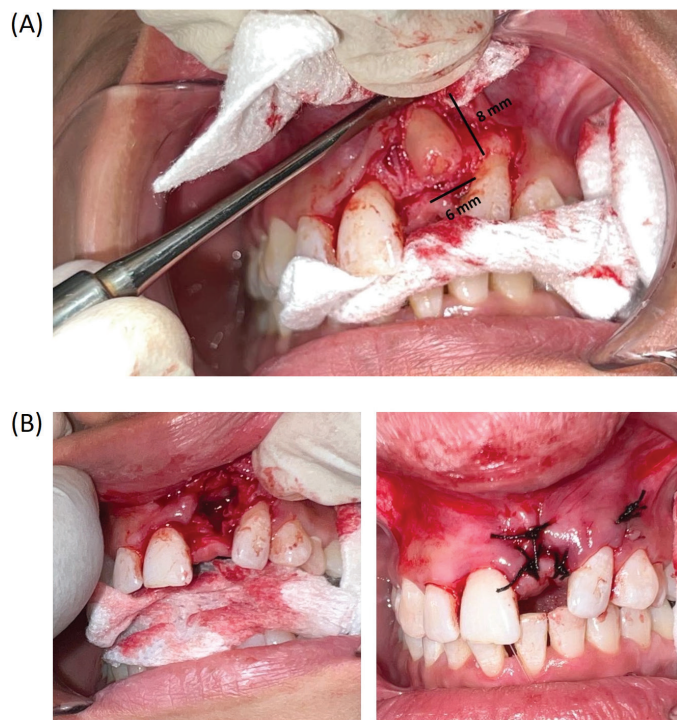


Figure 2. (A) The elevated buccal flap shows a dehiscence defect of the maxillary left central incisor root. (B) Postoperative images.

The tooth was luxated and removed in one piece with a straight elevator (Figure 2B). Finally, the surgical site was sutured with (#3/0) silk thread. The extracted tooth was examined and photographed. The crown was sound, and the root showed no signs of resorption. The cervical third of the root was angled to the rest of the tooth, confirming the diagnosis of a dilacerated tooth. Interestingly, the dilacerated tooth was found to have a 120° dilaceration angle (Figure 3).

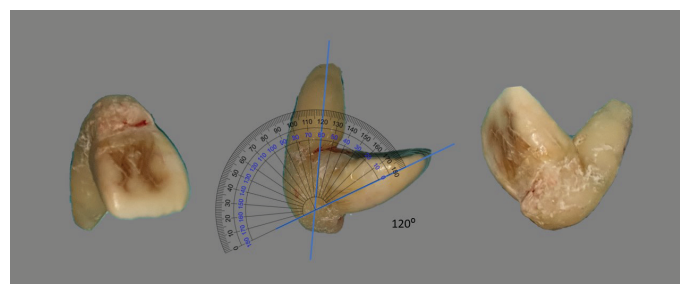


Figure 3. Dilacerated tooth images. The dilaceration angle was measured using a transparent protractor PNG image superimposed on the dilaceration angle.

The patient was recalled after one week for a review and the removal of sutures. Healing was progressing satisfactorily, and orthodontic treatment was planned (Figure 4).

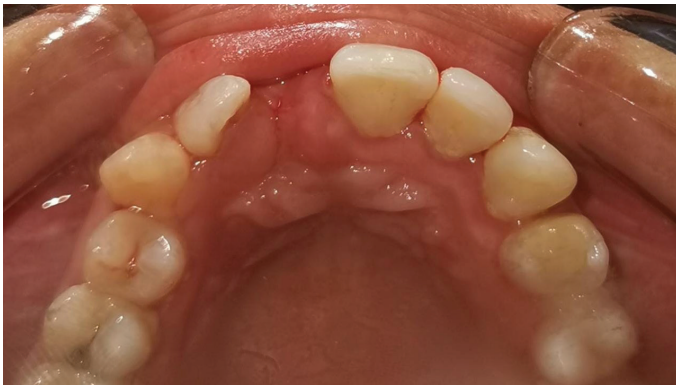

Figure 4. One week after surgery.

### 3. Discussion

The most common cause of tooth dilaceration is trauma [8]. Primary teeth injuries typically occur between the ages of 2–4 years, when the primary incisors are fully developed, and their root apices are very close to their permanent successors tooth germs. If the root comes into contact with the tooth germ, it can cause serious damage. The root of the primary tooth may cause significant damage if it comes into contact with the tooth germ [9,10].

The majority of dilaceration cases go unnoticed clinically. If the defect is so severe that the tooth is not capable of erupting, the only clinical indication will be a missing tooth [11]. Radiography is the most reliable method of detecting the condition. The condition would be easily spotted on a periapical radiograph if the root bends mesially or distally. This is clearly not the case if the root is bent labially or lingually where it gives the relatively difficult to diagnose “bull’s eye” appearance which is usually seen as radiopaque area with a dark shadow or a radiolucent center cast by the root canal space. This phenomenon is attributed to the fact that the X-ray beam central ray passes almost parallel with the deflected portion of the root [5].

In the present reported case of dilaceration, it was postulated that the traumatic incident identified by the patient’s past dental records may have caused the dilaceration just before the maxillary left central incisor

was due to erupt. The shape of the dilacerated root may have facilitated the dehiscence defect described above as the deflected root appears to have penetrated the thin labial bone at some point during the root maturation process. The odds of developing fenestration or dehiscence defects in the labial cortical plate increases the longer the primary predecessor tooth is retained [1]. A severely dilacerated tooth poses a significant surgical challenge for dentists because root fractures are likely to occur as a result. Typically, the preferred treatment option is to expose the tooth surgically followed by orthodontic treatment [12]. Nevertheless, an unerupted severely dilacerated tooth makes this treatment modality less favorable [13,14].

### 4. Conclusions

Tooth dilaceration is a challenging and complex dental condition that requires careful diagnosis and treatment. Childhood trauma is the most common cause of dilaceration, which can result in significant root damage and subsequent dental complications. While radiography is an effective diagnostic tool for detecting dilaceration, the shape and position of the dilacerated root can make diagnosis difficult. In cases of severely dilacerated teeth, a multidisciplinary approach is required due to the high risk of root fractures during treatment.

When an unerupted tooth is severely dilacerated at an angle greater than 90 degrees, surgical extraction remains the first-line treatment option. A minimally invasive approach may not be advisable in such cases. However, by establishing an accurate diagnosis and understanding the characteristic radiographical features of rare dental anomalies, complex cases can be successfully managed. Adhering to the basic principles of diagnosis and treatment is key to achieving a positive outcome.

### Authors’ contributions

This work has been carried out in collaboration between both authors. Both authors have read and approved the final manuscript.

### Conflict of interest

None to declare.



## References

- [1] N. Topouzelis, P. Tsousoglou, V. Pisoka, L. Zouloumis. Dilaceration of maxillary central incisor: a literature review. *Dental Traumatology*. 2010;26(5):427–33.
- [2] Ahmed HMA, Dummer PMH. A new system for classifying tooth, root and canal anomalies. Vol. 51, *International Endodontic Journal*. 2018.
- [3] Ashish Shrestha, Vinay Marla, Sushmita Shrestha, Iccha K Maharjan. Developmental anomalies affecting the morphology of teeth – a review. *RSBO*. 2016;12(1).
- [4] Hamasha AA, Al-Khateeb T, Darwazeh A. Prevalence of dilaceration in Jordanian adults. *Int Endod J*. 2002;35(11).
- [5] Malčić A, Jukić S, Brzović V, Miletić I, Pelivan I, Anić I. Prevalence of root dilaceration in adult dental patients in Croatia. *Oral Surgery, Oral Medicine, Oral Pathology, Oral Radiology and Endodontology*. 2006;102(1).
- [6] Qutieshat A, Al Harthy N, Javanmardi S, Singh G, Chopra V, Aoudidi R, et al. Prevalence of mesio-distal dilaceration in patients presenting for initial orthodontic care: A retrospective study. *J Orthod Sci*. 2023;12(1):1–5.
- [7] Mellara T de S, Nelson-Filho P, de Queiroz AM, Santamaria Júnior M, da Silva RAB, da Silva LAB. Crown dilaceration in permanent teeth after trauma to the primary predecessors: Report of three cases. *Braz Dent J*. 2012;23(5).
- [8] Jafarzadeh H, Abbott P V. Dilaceration: Review of an Endodontic Challenge. Vol. 33, *Journal of Endodontics*. 2007.
- [9] KILPATRICK NM, HARDMAN PJ, WELBURY RR. Dilaceration of a primary tooth. *Int J Paediatr Dent*. 1991;1(3).
- [10] Andrade MGS, Weissman R, Oliveira MG, Heitz C. Tooth displacement and root dilaceration after trauma to primary predecessor: An evaluation by computed tomography. *Dental Traumatology*. 2007;23(6).
- [11] White SC, Pharoah MJ. *White and Pharoah's Oral Radiology E-Book: Principles and Interpretation*. Elsevier. 2014;
- [12] Suksuphew S, Juntavee A. Impacted Maxillary Central Incisor: Surgical Exposure and Orthodontic Management: a Case Report. *KDJ*. 2010;13(1):49–57.
- [13] Punde PA, Patil NM, Pawar RL. Unusual presentation of “u-shaped” impacted maxillary central incisor with intranasal root: successful surgical management. *Ethiop J Health Sci*. 2014;24(3).
- [14] Rodríguez-Cárdenas YA, Arriola-Guillén LE, Ruíz-Mora GA, Aliaga-Del Castillo A, Boessio-Vizzotto M, Dias-Da Silveira HL. Root changes in buccal versus palatal maxillary impacted canines of adults: A longitudinal and retrospective 3-dimensional study before and after orthodontic traction. *Int Orthod*. 2020;18(3).