

# Interdisciplinary Approach To Unilateral Missing Maxillary Lateral Incisor With Preparation Modification (CASE REPORT)

<sup>1</sup>Mohamed Shaalan, <sup>2</sup>Ibrahim Allam and <sup>3</sup>Marwan Aggag

<sup>1,2</sup>Graduate Intern, College of Dentistry, Arab Academy for Science and technology & Maritime Transport, Egypt.

<sup>3</sup>Lecturer at Fixed Prosthodontics Department, College of Dentistry, Arab Academy for Science and technology & Maritime Transport, Egypt.

Emails: [mgamal0109m@gmail.com](mailto:mgamal0109m@gmail.com), [ibrahemallam177@gmail.com](mailto:ibrahemallam177@gmail.com), [marwanaggag@aast.edu](mailto:marwanaggag@aast.edu)

Received on, 14 July 2024 - Accepted on, 02 September 2024 - Published on, 19 September 2024

## ABSTRACT:

**Background:** In many clinical cases where one or both maxillary lateral incisors are absent, orthodontic treatment with space opening or closure using canine and premolar replacement has led to improved periodontal health and high patient satisfaction however with long treatment period. Preparation modification of the maxillary canine can simulate lateral incisor and first premolar can mimic the canine for appearance. Zirconia crowns have shown they can withstand occlusal and functional stresses while maintaining the required aesthetic appearance.

**Objectives:** This case highlighted management of unilateral missing maxillary lateral incisor with only preparation modification using digital smile design and CAD- CAM technology.

## KEYWORDS:

Interdisciplinary, missing lateral incisor, digital smile design, zirconia

## 1. Introduction

Congenitally missing maxillary lateral incisors pose a significant aesthetic and treatment challenge. Various factors, including age, location, space, the condition of the alveolar ridge, irregular gingival margins, occlusion and periodontal health, often require an interdisciplinary approach. [1]

Replacing missing lateral incisor by gaining the space for fixed or implant retained prosthesis is one treatment option but it requires prolonged care, maintenance and can become costly in the long run. Alternatively using canine substitution to close the space can help avoid these costs and

maintenance challenges. [2]

Primary concerns with orthodontic space closure include the risk of an unnatural appearance, difficulties with retention, and potential effects on functional occlusion. As a result, many dentists prefer to create space for missing lateral incisors, often choosing a single implant or a resin-bonded bridge as the preferred solution. [3, 4]

For maxillary lateral incisor missing teeth, conventional space gaining is a dependable method that usually yields long-term functional and cosmetic results that are satisfactory. [5, 6]

For missing maxillary lateral incisors, treatment options include maintaining and accepting the space, reshaping canines to function as lateral incisors and altering the first premolar to act as a canine. These strategies manage space for definitive restorations, potentially bypassing the need for orthodontics and facilitating future prosthetic solutions. [7]

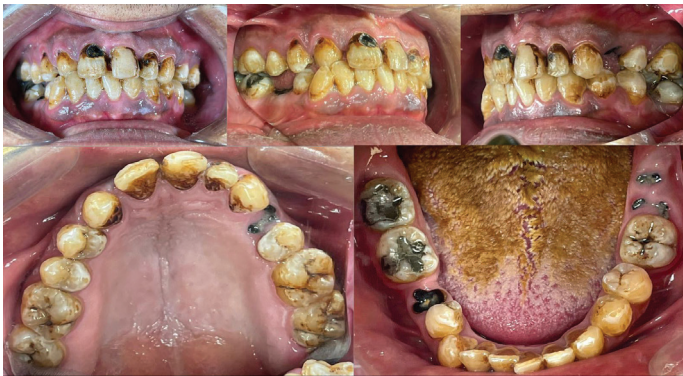This treatment alternative with the preparation modifications of maxillary canine substituting and camouflaging to mimic the lateral incisor. The first premolar can also be reshaped into a canine to improve the aesthetic durability. [6]

Dental ceramics are being used more frequently for anterior and posterior restorations due to the growing demand for aesthetic outcomes. Zirconia has especially gained popularity for crowns and bridges because of its superior aesthetic and biocompatibility. [8, 9] Top of Form Bottom of Form Zirconia has superior mechanical properties that made it more common compared to other ceramics. Using zirconia as a core material for crown enhances aesthetic, mechanical properties and biocompatibility. [10, 11]

## 2. Case and method

A 34-year-old male was referred to the College of Dentistry, AASTMT, Alamein. His primary concern was poor aesthetics in anterior teeth due to caries.

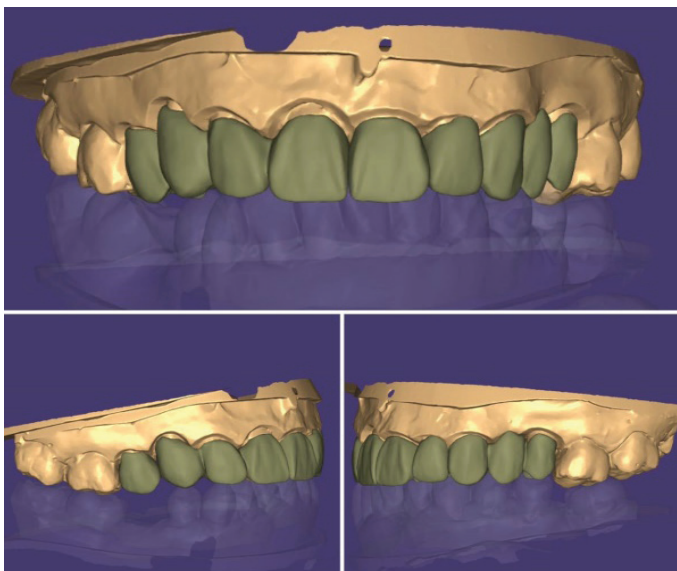
The preoperative condition of the maxillary and mandibular areas is shown in (Fig. 1). Following initial assessments and diagnosis with all required diagnostic tools (history, extraoral and intraoral examinations, mounted diagnostic casts, and radiographs) then the treatment plan was established.



**Fig. 1. Preoperative intraoral images**

Phase I: Involved examinations, making a diagnosis and finalizing the treatment plan. It also included Scaling, root planning and providing the patient with oral hygiene instructions. Excavation and elimination of all carious lesions and temporization with RMGI #17, 16, 15, 14, 13, 22, 23, 25, 26, 27, 37, and 44. Removal defective restoration #21.

To engage the patient and enhance motivation, a digital smile design was created for the anterior teeth, aligning with the patient's aesthetic preferences. This simulation illustrated the anticipated appearance of the final restoration (Fig. 2).



**Fig. 2 Digital smile design**

Phase II – Preparatory phase: Extraction of #24, 28, 38, and 45 and Endodontic treatment of tooth #11.

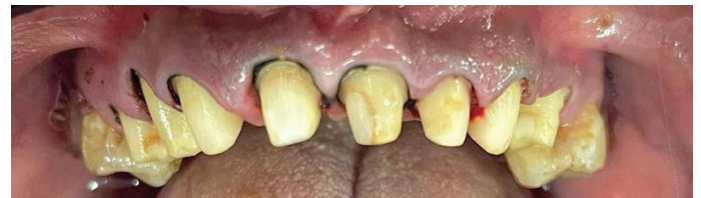Phase III – Definitive phase: Final Composite restoration for teeth: #17, 16, 15, 14, 13, 11, 21, 22, 23, 25, 26, 27, 37, and 44.

Subgingival deep chamfer finish line with rounded internal line angles was used to prepare the abutments for the zirconia crowns. [12]

The canine required additional reduction in both the incisogingival and mesiodistal dimensions, along with flattening of the labial surface and an increase in the steepness of the lingual convexity. With gentle and intermittent cutting and good cooling to avoid teeth hypersensitivity. [13] Digital smile design for determination of the amount of reduction and clearance is needed.

The first premolar dimensions need to be expanded mesiodistally and incisogingivally, while the palatal cusp requires reduction to avoid interferences during lateral movement. [13]

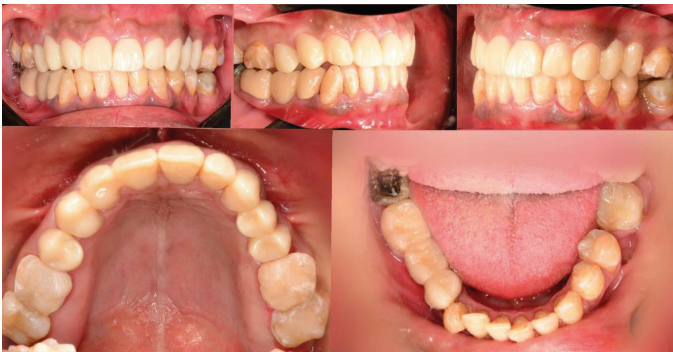Single 00 size retraction cord with a hemostatic agent was inserted into the sulcus to retract the soft tissue. Impressions were taken using heavy and light body polyvinyl siloxane (PVS) in a tray. An opposing impression was made with alginate and bilateral bite registrations were recorded with PVS (Fig. 3).



**Fig. 3. Preparation and soft tissue retraction**

Milled PMMA as provisional restoration was done according to the DSD. Computer aided design of the upper arch after pouring the model, a desktop bench scanner was used (Ceramill® Lab 600) to obtain a virtual model of the prepared arches.

For the maxillary crowns, full anatomic monolithic high translucent – (Zolid HT A2) were milled and mandibular fixed partial denture, full anatomic monolithic low translucent – (Zolid LT A2) were milled, and then were adhesively cemented using a self-adhesive, dual-cure resin cement (RelyX™ Unicem 2 Self-Adhesive Resin Cement, 3M, USA). The necessary occlusal adjustments were made to eliminate high points, ensuring uniform and consistent contact intensity (Fig. 4).



**Fig. 4. Final insertion of fixed restorations**

Phase IV: Maintenance and follow up was done by recalling the patient again at 1 week, 1 month, 3 months.

### 3. Discussion

Missing of one or both maxillary lateral incisors is a common finding affecting about 2% of the population. [14, 15]

Options for replacing a missing lateral incisor include creating space for an implant-supported prosthetic crown or closing the gap by mesializing the posterior teeth and reshaping the canine to mimic the lateral incisor. The choice of treatment depends on the patient's malocclusion, growth pattern, profile, smile line, and the size, shape, and color of their canines. [16]

It is essential to assess the treatment plan for functional, aesthetic, and periodontal acceptance while ensuring long-term stability. [17]

The primary benefit of space closure is that the treatment can be completed orthodontically preserving the natural state of both hard and soft tissues which may better adapt over time. However, this approach requires significant modifications to the canine including reduction in both incisogingival and mesiodistal dimensions, flattening of the labial surface and steepening of the lingual convexity then using composite, veneering or crown to replicate the missing tooth. Additionally, the premolar dimensions need to be increased mesiodistally and incisogingivally, while the palatal cusp should be removed. [18]

An alternative treatment involves creating space by distalizing the canine and preparing for a prosthetic replacement, [19, 20] often using dental implants. This approach usually results in successful outcomes, chiefly with patients who have healthy, intact neighboring teeth that are of normal size and shape. [21–23]

Implant placement in the anterior region demands precise technique and skill, as errors can lead to issues like incomplete papillary fill, bone loss, and gingival discoloration. [24, 25]

However, in this case, it was not feasible because the patient refused orthodontic treatment due to financial limitations and the patient needs full mouth rehabilitation and necessitate preparation for all his maxillary teeth except molars due to high caries risk. Fortunately, the ideal position of the canine was successfully achieved. The treatment included adjusting the incisal edge of the canine and reshaping it to resemble the maxillary lateral incisor. [26, 27] this involved grinding the labial surface to match the lateral incisor shape and eliminate its two planes. Additionally, the palatal surface was modified to ensure proper occlusion. [27]

During the restoration of the maxillary lateral incisor, the researchers adhered to Chu's proportion, which indicates that the maxillary canine should be one millimeter wider than the lateral incisor. To achieve this, both mesial and distal surfaces of the canine were ground by 0.5 mm each to reach the desired width. The first premolar was recontoured to function as a canine by intruding and reshaping it to reestablish canine guidance. Careful reduction was performed using new diamond burs with cooling to avoid exposing dentin and damaging adjacent teeth. [28].

### 4. CONCLUSION

The recommended course of treatment in this instance has shown to be dependable and effective. Modifying the canine and first premolar preparation with digital smile design can avoid the need for orthodontic treatment in cases of congenitally missing maxillary lateral incisors. Zirconia is advised to use long-term clinical applications to better objectively assess the outcomes of this instance.

#### CONFLICT OF INTEREST:

There are no conflicts of interest, according to the writers.

#### FUNDING:

For this work, the authors did not receive any special funding.



## 5. REFERENCES

1. Mantzikos T, Shamus I. Case report: Forced eruption and implant site development. *Angle Orthodontist*. 1998;68(2).
2. Savarrio L, McIntyre GT. To open or to close space--that is the missing lateral incisor question. *Dent Update*. 2005;32(1).
3. Millar BJ, Taylor NG. Lateral thinking: The management of missing upper lateral incisors. *Br Dent J*. 1995;179(3).
4. Bishara SE, Ortho. D. Impacted maxillary canines: A review. Vol. 101, *American Journal of Orthodontics and Dentofacial Orthopedics*. 1992.
5. Robertsson S, Mohlin B. The congenitally missing upper lateral incisor. a retrospective study of orthodontic space closure versus restorative treatment. *Eur J Orthod*. 2000;22(6).
6. Zachrisson BU, Rosa M, Toreskog S. Congenitally missing maxillary lateral incisors: Canine substitution. Vol. 139, *American Journal of Orthodontics and Dentofacial Orthopedics*. 2011.
7. Acar O, Tuncer D, Sahinoglu Z, Ozcirpici AA, Arhun N. Assessing Treatment Options of Congenitally Missing Lateral Incisors: Shall We Create or Eliminate the Space? *The Journal of Dentists*. 2014;2(2).
8. Bona A Della, Pecho OE, Alessandretti R. Zirconia as a dental biomaterial. Vol. 8, *Materials*. 2015.
9. Khalifa A, Aggag M. FULL MOUTH REHABILITATION USING CAD-CAM SURVEYED ZIRCONIA CROWNS AND A REMOVABLE PARTIAL DENTURE (CASE REPORT). *Alexandria Dental Journal*. 2022;0(0).
10. Blatz MB. Long-term clinical success of all-ceramic posterior restorations. *Quintessence Int*. 2002;33(6).
11. Takeichi T, Katsoulis J, Blatz MB. Clinical outcome of single porcelain-fused-to-zirconium dioxide crowns: A systematic review. *Journal of Prosthetic Dentistry*. 2013;110(6).
12. Paek J, Noh K, Pae A, Lee H, Kim HS. Fabrication of a CAD/CAM monolithic zirconia crown to fit an existing partial removable dental prosthesis. *Journal of Advanced Prosthodontics*. 2016;8(4).
13. Zachrisson BU, Rosa M, Toreskog S. Congenitally missing maxillary lateral incisors: Canine substitution. *American Journal of Orthodontics and Dentofacial Orthopedics*. 2011 Apr;139(4):434–44.
14. Goodman Jane R, Jones Steven P, Hobkirk John A., King P. Hypodontia: I. Clinical features and the management of mild to moderate hypodontia. *Medicine*. 1994;
15. Polder BJ, Van't Hof MA, Van Der Linden FPGM, Kuijpers-Jagtman AM. A meta-analysis of the prevalence of dental agenesis of permanent teeth. *Community Dent Oral Epidemiol*. 2004;32(3).
16. Johal A, Katsaros C, Kuijpers-Jagtman AM. State of the science on controversial topics: Missing maxillary lateral incisors - a report of the Angle Society of Europe 2012 meeting. *Prog Orthod*. 2013;14(1).
17. Abu-Husein M, Watted N, Hegedus V, Borbely P. Congenitally missing upper laterals . Clinical considerations - : Orthodontic Space Closure. *Journal of Dental and Oral Health*. 2015;1(3).
18. Zachrisson BU, Rosa M, Toreskog S. Congenitally missing maxillary lateral incisors: Canine substitution. *American Journal of Orthodontics and Dentofacial Orthopedics*. 2011 Apr;139(4):434–44.
19. Kokich VG. Maxillary lateral incisor implants: Planning with the aid of orthodontics. *Journal of Oral and Maxillofacial Surgery*. 2004;62(SUPPL. 2).
20. Kokich VO, Kinzer GA, Janakievski J. Congenitally missing maxillary lateral incisors: Restorative replacement. *American Journal of Orthodontics and Dentofacial Orthopedics*. 2011 Apr;139(4):435–45.
21. Ostler MS, Kokich VG. Alveolar ridge changes in patients congenitally missing mandibular second premolars. *J Prosthet Dent*. 1994;71(2).
22. Henry PJ, Laney WR, Jemt T, Harris D, Krogh PH, Polizzi G. Osseointegrated implants for single-tooth replacement: a prospective 5-year multicenter study. *Int J Oral Maxillofac Implants*. 1996;

23. Garber DA, Salama MA, Salama H. Immediate total tooth replacement. *Compend Contin Educ Dent.* 2001;22(3).
24. Sabri R. Management of missing maxillary lateral incisors. *Journal of the American Dental Association.* 1999;130(1).
25. Grunder Ueli, Gracis Stefano, Capelli Matteo. Influence of 3-D Bone-to-Implant Relationship on Esthetics. *Int J Periodontics Restorative Dent.* 2005;
26. Araújo EA, Oliveira DD, Araújo MT. Diagnostic protocol in cases of congenitally missing maxillary lateral incisors. *World J Orthod.* 2006;7(4).
27. Chu SJ, Tan JHP, Stappert CFJ, Tarnow DP. Gingival zenith positions and levels of the maxillary anterior dentition. *Journal of Esthetic and Restorative Dentistry.* 2009;21(2).
28. Chu SJ. Range and mean distribution frequency of individual tooth width of the maxillary anterior dentition. *Pract Proced Aesthet Dent.* 2007;19(4).